

Research Article

Melatonin as adjuvant treatment for coronavirus disease 2019 pneumonia patients requiring hospitalization (MAC-19 PRO): a case series

Rafael R. Castillo*^{1,2,4}, Gino Rei A. Quizon^{^ 1}, Mario Joselito M. Juco¹, Arthur Dessi E. Roman¹, Donnah G. de Leon¹, Felix Eduardo R. Punzalan^{1,3}, Rafael Bien L. Guingon¹, Dante D. Morales^{1,5}, Dun-Xian Tan⁶, Russel J. Reiter⁷; on behalf of the MAC-19 PRO Study Group

¹ Department of Internal Medicine, Manila Doctors Hospital, Manila, Philippines

² Cardiovascular Medicine, Adventist University of the Philippines, College of Medicine, Silang, Philippines

³ University of the Philippines, College of Medicine; Manila, Philippines

⁴ CardioMetabolic Research Unit (CaMeRU), FAME Leaders Academy, Makati, Philippines

⁵ Section of Cardiology, Makati Medical Center, Makati, Philippines

⁶ S.T. Bio-Life; San Antonio, Texas, USA

⁷ Department of Cell Systems and Anatomy, UT Health San Antonio, San Antonio, Texas, USA

[^]Joint first author

*Correspondence: rafael.castillo@fame.ph, medicalfiles.inquirer@gmail.com, Tel: +63 917 886 8409

Running Title: Adjuvant melatonin treatment in COVID19 pneumonia

Received: April 30, 2020; Accepted: June 3, 2020

ABSTRACT

Treatment for coronavirus disease 2019 (COVID19) pneumonia remains empirical and the search for therapies that can improve outcomes continues. Melatonin has been shown to have anti-inflammatory, antioxidant, and immune-modulating effects that may address key pathophysiologic mechanisms in the development and progression of acute respiratory distress syndrome (ARDS), which has been implicated as the likely cause of death in COVID19. We aimed to describe the observable clinical outcomes and tolerability of high-dose melatonin (hdM) given as adjuvant therapy in patients admitted with COVID19 pneumonia. We conducted a retrospective descriptive case series of patients who: 1) were admitted to the Manila Doctors Hospital in Manila, Philippines, between March 5, 2020 and April 4, 2020; 2) presented with history of typical symptoms (fever, cough, sore throat, loss of smell and/or taste, myalgia, fatigue); 3) had admitting impression of atypical pneumonia; 4) had history and chest imaging findings highly suggestive of COVID19 pneumonia, and, 5) were given hdM as adjuvant therapy, in addition to standard and/or empirical therapy. One patient admitted to another hospital, who one of the authors helped co-manage, was included. He was the lone patient given hdM in that hospital during the treatment period. Main outcomes described were: time to clinical improvement, duration of hospital stay from hdM initiation, need for mechanical ventilation (MV) prior to cardiopulmonary resuscitation, and final outcome (death or recovery/discharge). Of 10 patients given hdM at doses of 36-72mg/day per os (p.o.) in 4 divided doses as adjuvant therapy, 7 were confirmed COVID19 positive (+) by reverse transcription polymerase chain reaction (RT-PCR) and 3 tested negative (-), which was deemed to be false (-) considering the patients' typical history, symptomatology, chest imaging

findings and elevated bio-inflammatory parameters. In all 10 patients given hdM, clinical stabilization and/or improvement was noted within 4-5 days after initiation of hdM. All hdM patients, including 3 with moderately severe ARDS and 1 with mild ARDS, survived; none required MV. The 7 COVID19(+) patients were discharged at an average of 8.6 days after initiation of hdM. The 3 highly probable COVID19 patients on hdM were discharged at an average of 7.3 days after hdM initiation. Average hospital stay of those not given hdM (non-hdM) COVID19(+) patients who were admitted during the same period and recovered was 13 days. To provide perspective, although the groups are not comparable, 12 of the 34 (35.3%) COVID19(+) non-hdM patients admitted during the same period died, 7/34 (20.6%) required MV; while 6 of 15 (40%) non-hdM (-) by RT-PCR but highly probable COVID19 pneumonia patients also died, 4/15 (26.7%) required MV. No significant side-effects were noted with hdM except for sleepiness, which was deemed favorable by all patients, most of whom had anxiety- and symptom-related sleeping problems previously. HdM may have a beneficial role in patients treated for COVID19 pneumonia, in terms of shorter time to clinical improvement, less need for MV, shorter hospital stay and possibly lower mortality. HdM was well tolerated. This is the first report describing the benefits of hdM in patients being treated for COVID19 pneumonia. Being a commonly available and inexpensive sleep-aid supplement worldwide, melatonin may play a role as adjuvant therapy in the global war against COVID19.

Key words: melatonin, COVID19 pneumonia, adjuvant therapy, cytokine storm, immune system.

1. INTRODUCTION

The main cause of death in severe COVID19 is due to progressive acute lung injury (ALI) and acute respiratory distress syndrome (ARDS) (1, 2), likely triggered by excessive inflammatory and immune responses activating a so-called “cytokine storm” (2, 3). Treatment for COVID19 remains supportive and empirical, and the search for therapies that will improve outcomes continues (4).

Melatonin is an inexpensive sleep-aid supplement commonly available worldwide. It is known for its anti-inflammation (5-8), anti-oxidation (5) and immune-enhancing effects (9-11). It has been shown to reduce the pro-inflammatory cytokines tumor necrosis factor (TNF)- α , interleukin (IL)-1 β , IL-6, and IL-8, and increase the level of the anti-inflammatory cytokine IL-10 (5-8). Safety of melatonin in humans up to doses exceeding 100mg/day has been demonstrated (5, 12, 13).

With the known rapidly progressive pathophysiology of severe COVID19 that could be possibly addressed by the anti-inflammatory, antioxidant and immune-modulatory effects of melatonin, this study determined the efficacy and tolerability of high-dose melatonin (hdM) as an adjuvant therapy in patients admitted for COVID19 pneumonia.

2. METHODS

We reviewed the charts of all patients who : 1) were admitted to the Manila Doctors Hospital in Manila, Philippines, between March 5, 2020 and April 4, 2020; 2) presented with history of typical symptoms (fever, cough, sore throat, loss of smell and/or taste, myalgia, fatigue); 3) had admitting impression of atypical pneumonia; 4) had history and chest imaging findings (ground glass opacities in both lung fields) highly suggestive of COVID19 pneumonia, and, 5) were given hdM as adjuvant therapy, in addition to standard and/or empirical therapy. One patient, who one of the authors helped co-manage and was admitted to the University of the

East Ramon Magsaysay Memorial Center, also in Metro Manila, was included in the case series. He was the lone patient given hdM in that hospital during the same period.

Main outcomes noted were: time to clinical improvement (symptomatic improvement or relief, stabilization and/or regression of lung infiltrates by chest x-ray or computed tomography scan, decrease in bio-inflammatory laboratory parameters), need for mechanical ventilation (MV), duration of hospital stay after hdM initiation, and final outcome (death, or recovery and discharge) in all patients given hdM.

To provide perspective, although the groups are not comparable, the mortality rates of hdM patients and those not given hdM (non-hdM) were also determined.

3. RESULTS

Of the 58 patients admitted to our institution between March 5, 2020 to April 4, 2020 for recent history of flu-like symptoms symptoms (fever, cough, sore throat, loss of smell and/or taste, myalgia, fatigue) and chest imaging findings of ground glass opacities highly suggestive of COVID19 pneumonia, 9 (15.5%) were given hdM—3 patients on admission and the 6 others, during the course of their hospital stay when no clinical improvement was observed with the standard and empirical treatments they were receiving. HdM was administered at doses between 36 mg/day to 72 mgs/day per os (p.o.) in 4 divided doses. Another COVID19 positive (+) patient identified by reverse transcription polymerase chain reaction (RT-PCR), admitted to another hospital, who one of the authors helped co-manage, was also included in this case series. He was the lone patient given hdM in that hospital during the same period. Of the total of 10 patients given hdM, 7 were confirmed RT-PCR(+), while 3 tested negative(-), but considering their history and clinical presentation including chest imaging findings, treatment for COVID19 pneumonia was continued. Three of the 7 given hdM had moderately severe ARDS (pO₂/FiO₂ < 200 mm Hg). The 10 patients given hdM had high-risk features: >60 years of age, or younger but with established cardiovascular disease or other comorbidities including diabetes mellitus, hypertension, chronic obstructive pulmonary disease, chronic kidney disease, bronchial asthma and obesity (Table 1).

Table 1. Patient demographics, comorbidities, laboratory findings.

P	H	Age/ Sex	Comor- bidities	Max O ₂ supply	Chest Xray	CT scan	V	ABG (worst)	CBC	Procal	Inflam-I (LDH, CRP, Ferritin)
1	8	64/ M	HTN T2DM CKD Gout	Face Mask 10 lpm	Pulmonary Edema	Diffusely distributed GGO exhibiting “crazy paving” pattern and areas of beginning consolidation on both lungs	+	pH 7.45 pCO ₂ 36.2 HCO ₃ 25.3 pO ₂ 70.9 O ₂ sat 93.4 PF ratio 158	Hgb 115 Wbc 7.77 Neu 71 Lym 20 PC 392	< 0.05	LDH 454(451)(525)(540) hsCRP 30.8 (69) (61) (134) Ferritin 922.16 (1529.75)
2	8	64/ F	HTN IFG BANIAE Gout	NC 2 lpm	Bilateral Pneumonia	GGO diffusely scattered in both lungs	+	pH 7.423 pCO ₂ 33.0 HCO ₃ 21 pO ₂ 156 O ₂ sat 98.5 PF ratio	Hgb 129 Wbc 6.09 Neu 59 Lym 27 PC 431	<0.05	LDH 296 hsCRP 16.87 Ferritin 301.33
3	5	68/ M	HCVD IFG	NC 2 lpm	Bilateral Infiltrates	Consolidated GGO scattered in both lung fields	+	pH 7.455 pCO ₂ 33.7 HCO ₃ 23.4 pO ₂ 77.5 O ₂ sat 95 PF ratio 375	Hgb 120 Wbc 9.44 Neu 70 Lym 18 PC 352	<0.05	LDH 183 (232) hsCRP 7.71 (32.62) 793 (817) (902)
4	6	61/ F	(-)	NC 1 lpm	Bilateral infiltrates	Bilateral parenchymal GGO and consolidation Pneumonia	+	pH 7.450 pCO ₂ 33.8 HCO ₃ 23.4 pO ₂ 99.2 O ₂ sat 97.9 PF ratio 472	Hgb 129 Wbc 4.91 Neu 53 Lym 29 PC 415	<0.05	LDH 226 (238) (236) hsCRP 5.51 (4.38) Ferritin 429.71

5	9	26/ M	HPN s/pCVD BAIAE	NC lpm 2	Bilateral infiltrates	Patchy GGO with mixed consolidation in right middle lobe and inferior lingula	+	pH 7.494 pCO ₂ 34.4 HCO ₃ 26.2 pO ₂ 104 O ₂ sat 97 PF ratio 371	Hgb 157 Wbc 3.07 Neu 67 Lym 29 PC 222	0.06	LDH 294 (348)(268)(208 (215) hsCRP 0.13 (6.35)(13.29 Ferritin 1154 PC (757)(663)(389)
6	5	52/ F	HTN s/p MI (2015)	Room air	Bilateral infiltrates	Subtle GGO in the superior segment of the right lower lobe and inferior lingula	-	pH 7.421 pCO ₂ 35.1 HCO ₃ 22.4 pO ₂ 101 O ₂ sat 97.6 PF ratio 505	Hgb 112 Wbc 9.65 Neu 62 Lym 28 PC 271	<0.05	LDH 164 hsCRP 1.14 Ferritin none
7	11	76/ M	HCVD, CAD, BANIAE	NC lpm 6	Reticular infiltrates mid to LLL and RLLF	GGO bilateral upper and Right middle lobe and lingula	+	pH 7.518 pCO ₂ 28.8 HCO ₃ 23.2 pO ₂ 65.4 O ₂ sat 93.5 PF ratio 148	Hgb 137 Wbc 9.05 Neu 73 Lym 9 PC 218	<0.05	LDH 212(268)(277)(182) hsCRP 118 (129)(109)(38) Ferritin 869 (852) (627)
8	5	62/ F	HTN	Room air	Reticular infiltrates on both lower lobes with patchy GGO in RUL	Few reticular and GGO in the superior segment, anterior and medial basal segment of the Right lower lobe and posterior segment of the left lower lobe.	-	pH 7.438 pCO ₂ 37 HCO ₃ 24.6 pO ₂ 93 O ₂ sat 96.9 PF ratio 465	Hgb 141 Wbc 6.26 Neu 47 Lym 40 PC 306	<0.05	LDH 212 iu/L Ferritin 108
9	11	54/ F	HTN T2DM BANIAE Microvas- cular ischemia with paroxysmal arrhythmia	NC lpm 3	Bilateral infiltrates	Multifocal reticular and GGO with signs of early peripheral consolidation scattered in both lung fields.	-	pH 7.42 pCO ₂ 35 HCO ₃ 22 pO ₂ 53 O ₂ sat 88 PF ratio 252	Hgb 140 Wbc 8.78 Neu 63 Lym 25 PC 338	<0.05	LDH 240 hsCRP 1.47 Ferritin 393
10 [#]	9	70/ M	HTN T2DM COPD (current smoker)	Face mask 10 lpm	Interstitial hazed opacities in the bilateral mid lung fields; infiltrates in the right lower lung	GGO, both lungs, bibasal subsegmental atelectatic changes; enlarged mediastinal lymph nodes	+	pH 7.46 pCO ₂ 33 HCO ₃ 23.5 pO ₂ 72 O ₂ sat 95 at 8 lpm by NC PF ratio 138	Hgb 141 Wbc 3.9 Neu 60 Lym 40 PC 170	0.11	LDH 277 CRP 23.25 Ferritin 3,190

P: patient's No., H: Hospital stay (Days) from start of hdM to discharge, V: SARS-CoV-2 virus test, Inflam-I: inflammatory indexes, #: Patient admitted in another hospital, HTN: Hypertension, HCVD: Hypertensive Cardiovascular Disease, IFG: Impaired Fasting Glucose, T2DM: Type 2 Diabetes Mellitus, MI: Myocardial Infarction, BAIAE: Bronchial Asthma in acute exacerbation, BANIAE: Bronchial Asthma not in acute exacerbation, CKD: Chronic Kidney Disease, LLLF: left lower lung field, RLLF: right lower lung field, GGO: ground glass opacities, NC: nasal cannula, (): Previous lab results, hdM: High dose melatonin.

Of the 58 patients admitted to our institution for COVID19 pneumonia during the same period, 40 (69%) were confirmed by RT-PCR to be COVID19 (+), while 18 (31%) were (-). All patients were given standard and/or empirical treatment as deemed appropriate by the attending medical teams — composed of an infectious disease specialist, a pulmonologist, and other referral consultants depending on the patients' comorbidities. The treatment regimen consisted of any of the following as needed: supplemental oxygen, MV, agents to mitigate cytokine storm, oral or parenteral antibiotics, anti-viral agents; vasopressor support, renal-replacement therapy, and hemoperfusion/hemadsorption. (Table 2).

Table 2. Dose of melatonin and other drugs given.

P	Dose of Mel	Mel use at admission	Blood Culture	Antibiotics	Chl/HChl	Azithromycin	Lopinavir/ritonavir	Oseltamivir	Na ascorbate Zinc	IL6-inhibitor (Tocilizumab)	Hemoperfusion
1	60 mg/day	Day 1	No Growth	Pip-Tazo	-	+	+	+	+	+	+
2	36 mg/day	Day 1	No Growth	Pip-Tazo Ceftriaxone	HChl	+	+	+	-	-	-
3	48 mg/day	Day 4	No Growth	Meropenem	Chl	+	+	+	-	-	-
4	36 mg/day	Day 11	No Growth	Meropenem Pip-Tazo	Chl	+	+	-	-	+	-
5	60 mg/day	Day 3	No Growth	Meropenem	HChl	-	+	+	-	+	-
6	36 mg/day	Day 1	No Growth	Pip-Tazo	HChl	+	-	-	+	-	-
7	36 mg/day	Day 7	No Growth	Meropenem Pip-Tazo	HChl	+	-	+	+	-	-
8	48 mg/day	Day 1	No Growth	Ceftriaxone	HChl	+	-	+	+	-	-
9	72 mg/day	Day 1	No Growth	Ceftriaxone	-	+	+	-	+	-	-
10 [#]	60 mg/day	Day 4	No Growth	Pip-Tazo	HChl	+	+	-	+	-	-

P: Patient's No., *#*: Patient admitted in another hospital, +: Drugs given, -: Not given, Pip-Tazo: Piperacillin-Tazobactam, Mel: melatonin, Chl: chloroquine, HChl: hydroxychloroquine.

Clinical stabilization and/or improvement was noted within 4-5 days after initiation of hdM in all COVID19(+) patients and highly probable but COVID19 (-) patients given the supplement. None required MV. All 10 patients given hdM survived and the 7 COVID19(+) patients were discharged at an average of 8.6 days after initiation of hdM including 3 with moderately severe ARDS. The 3 highly probable but COVID19 (-) patients given hdM, one of whom also developed mild ARDS ($pO_2/FiO_2 < 300$ mm Hg), were discharged clinically improved and asymptomatic at an average of 7.3 days after hdM initiation. The average hospital stay of non-hdM COVID19(+) patients who recovered was 13 days.

To provide perspective, although both groups are not comparable, 12 of the 34 (35.3%) COVID19(+) non-hdM patients admitted in our institution during the same period died, 7/34 (20.6%) required MV; while 6 of 15 highly probable but COVID19 (-) non-hdM patients (40%) died, 4/15 (26.7%) required MV.

No significant side-effects were noted in those given hdM except for increased sleepiness.

4. DISCUSSION

Published research suggests the versatility of melatonin as an anti-inflammatory, antioxidant and immuno-modulating agent (5-11). The beneficial effects of hdM as adjuvant therapy in cancer (13-15), severe viral influenza (5, 8) and sepsis (8) have also been demonstrated. Melatonin increases p53/p21Waf1 (wild type p53/21 activated fragment) expression causing anti-proliferative effects in breast cancer cells (16). Moreover, other mechanisms were also identified such as inducing apoptosis in MCF (Michigan Cancer Foundation)-7 human breast cancer cells, and anti-estrogenic effects to $E\alpha$ signaling pathway (17). In 1997, *Lisson et al.* (18) published a study wherein breast cancer patients were given melatonin 20 mg/day at bedtime as adjunctive treatment for chemotherapy. The authors concluded that patients given melatonin had less thrombocytopenia, stomatitis and neuropathy, with no significant adverse reactions (19).

In several animal models, melatonin protects against bacterial, viral and parasitic infection through immunomodulation and/or direct or indirect anti-oxidant activity (20). The production

of reactive oxygen species (ROS) is one of the lethal effects of any severe infection. Melatonin has shown beneficial effects in sepsis by decreasing the synthesis of pro-inflammatory cytokines and suppressing inducible nitric oxide (NO) synthase gene expression (21). In a study done by Carrillo-Vico *et al.* administration of melatonin (10mg) to mice with lipopolysaccharide induced inflammation showed 90% survival. This may be due to the increased levels of anti-inflammatory cytokine interleukin (IL)-10 and decreased concentration of proinflammatory mediators such as TNF, IL-12, and interferon- γ (21). A study in septic newborns performed by Gitto *et al.* showed that malondialdehyde (MDA), nitrite production and 4-hydroxylalkenals (HDA) were significantly reduced in those patients given melatonin. Moreover, melatonin administration also improved the clinical outcome of those septic newborns (22).

This is the first report on the actual use of hdm in humans afflicted with COVID19 pneumonia. Melatonin is not a direct viricidal agent; but it may help neutralize the deleterious effects of the SARS-CoV-2 that causes COVID19 (5). It may particularly mitigate the maladaptive immune-modulatory response that releases pro-inflammatory cytokines and chemokines triggering a 'cytokine storm' that causes extensive multiorgan damage particularly in the lungs (5-8). Zhang *et al.* postulated that following SARS-CoV-2 infection, ALI/ARDS may result due to a suppressed immune response, excessive inflammation and uncontrolled oxidation resulting in a cytokine storm (5). Melatonin may exert a beneficial role as adjuvant therapy in the regulation of the immune system, inflammation and oxidation stress, to mitigate the complications of ALI/ARDS and related multi-organ complications (5) (Figure 1).

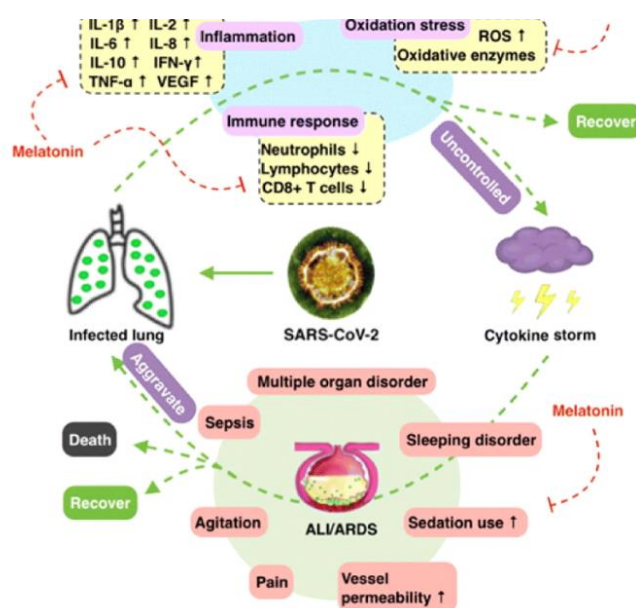


Fig. 1. Pathogenesis of COVID-19 and potential adjuvant use of melatonin.

Zhang R *et al.* (5) postulated that following SARS-CoV-2 infection, ALI/ARDS may occur due to a suppressed immune response, excessive inflammation and uncontrolled oxidation activating a cytokine storm. Melatonin may exert a beneficial role as adjuvant therapy in the regulation of the immune system, inflammation and oxidation stress, to mitigate the complications of ALI/ARDS and related multi-organ complications. ALI: Acute lung injury; ARDS: Acute respiratory distress syndrome. (Figure is reproduced from (5) with permission).

Secondary hemophagocytic lymphohistiocytosis (sHLH) is a hyperinflammatory syndrome characterized by a fatal hypercytokemia with multiorgan failure. Clinically, it is manifested by unremitting fever, cytopenias, hyper-ferritinemia and in half of patients, ARDS (2). This sHLH

closely resembles the cytokine storm associated with COVID19. In the early stage of coronavirus infection, dendritic and epithelial cells are activated and express a cluster of pro-inflammatory cytokines and chemokines which is manifested as an increase in IL-1 β , IL-2, IL-6, IL-8, both IFN- α / β , TNF, CcC motif chemokine 3 (CCL3), CCL5, CCL2, and IP-10 (5) which then contributes to the development of the disease. IL-10 is antiviral; and usually in coronavirus infection, this interleukin is decreased (23, 24). However, in some COVID19 patients, elevated levels of IL-10 have been noted. It is still unknown whether this is a unique feature of COVID19 (24). A marked decrease in IL-10, results in amplification of inflammatory response which then promotes cellular apoptosis or necrosis of the affected cells that lead to increased permeability of blood vessels and aberrant accumulation of inflammatory monocytes, macrophages and neutrophils in the lung alveoli causing ALI. In a study by Smits et.al, they noted that the severity of ALI was accompanied by an elevated expression of inflammatory cytokine, IFN β , rather than the viral load (25). Another study by Channappanavar et.al, noted that the depletion of inflammatory monocytes caused an increased survival rate of coronavirus host without a change in viral load (26). This signifies that if the same mechanism is involved in COVID19, and inhibiting several cytokines may lead to improved outcomes. This is where melatonin may play a big role in COVID19.

Melatonin has anti-inflammatory effects through different pathways. Sirtuin-1 (SIRT1) mediates melatonin's anti-inflammatory action by inhibiting high mobility group box 1 protein 1 (HMGB1) leading to attenuation of pro-inflammatory macrophages (27). In a study done by Wang *et al.*, regulation of SIRT1 in sepsis-induced ALI reduced lung injury and inflammation. Another mechanism of melatonin is through nuclear factor kappa-B (NF- κ B). NF- κ B is an inflammatory mediator in ALI and melatonin has been shown to downregulate NF- κ B in T cells and lung tissues (28, 29). Moreover, melatonin has an anti-oxidative effect through upregulating anti-oxidative enzymes and downregulating pro-oxidative enzymes (5). In viral infections, virus replication generates oxidized products. In SARS-induced lung injury, there is a production of oxidized low-density lipoprotein which then activates innate immune response causing overproduction of IL-6 in alveolar macrophages via toll-like receptor 4 (TLR4) leading to ALI (29). TLR4 is a therapeutic target for melatonin. In a study by Zhao *et al.*, melatonin was shown to exert an anti-inflammatory and antioxidant effect reducing damage to the white matter after focal brain ischemia in rats by regulating the TLR4/NF- κ B pathway (30). Thus, it is likely that administration of melatonin will be beneficial in attenuating the inflammation and oxidation in COVID19 patients.

In Patients 3, 4, 5, 7, 10 who received hdM, the supplement was added to the regimen when clinical improvement was not noted with the standard and empirical drugs the patients were taking (Table 1, 2). In those patients, a temporal relationship between hdM initiation and clinical improvement was observed. Symptomatic improvement was observed after 48-72 hours, soon followed by a decrease in bio-inflammatory parameters.

The regression of ground glass opacities (infiltrates) on chest imaging was observed last. The most frequent chest x-ray and computerized tomography scan findings of interstitial changes and ground glass opacities (GGOs) may occur early in the course of COVID19 pneumonia and have been observed to peak around 10 to 14 days after the onset of symptoms (31-35). However, the radiologic changes may persist even when the patients have already improved clinically and even up to the time of discharge (34). This was noted in most of the patients in this series despite the marked symptomatic relief and decrease in bio-inflammatory parameters. In Patient No. 1 in the series, a 64-year old male diabetic, hypertensive with chronic kidney disease and chronic gout, who had moderately severe ARDS on admission, serial chest x-rays showed bilateral infiltrates/GGOs persisting up to discharge but showing some regression (Figure 2). However, patient was already symptom-free by the fifth hospital day

with decreasing bio-inflammatory parameters. Thus, regression of chest imaging abnormalities could not be correlated with clinical improvement due to a radiologic lag when compared with other clinical parameters.

It may also be noteworthy that the 10 patients given hdM in this case series all had high risk features: > 60 years of age, or < 60 years of age and with established cardiovascular disease or comorbidities, which have been associated with an increased risk for mortality in COVID19. Three of the 10 hdM patients had moderately severe ARDS, and another one had mild ARDS. None of the 10 given hdM required MV.

In Wuhan, China, age and comorbidities were highly contributory factors among those who died from COVID19 (36, 37). A retrospective, multicenter cohort study done by Zhou *et al.* which included 191 adult in-patients (≥ 18 years old) with laboratory confirmed COVID19 from Jinyintan Hospital and Wuhan Pulmonary Hospital (Wuhan, China) showed that the following factors: older age (odds ratio 1.10, 95% CI 1.03–1.17, per year increase; $p=0.0043$), higher Sequential Organ Failure Assessment (SOFA) score (5.65, 2.61–12.23; $p<0.0001$), and d-dimer greater than 1 $\mu\text{g/mL}$ (18.42, 2.64–128.55; $p=0.0033$) on admission were associated with in-hospital mortality (36, 37). This was attributed to the age-dependent defects in T-cell and B-cell function coupled with the excessive production of type 2 cytokines that promoted viral replication and more pronounced pro-inflammatory responses, contributing to an unfavorable outcome. Moreover, the aging process especially when accompanied by comorbidities such as diabetes mellitus and hypertension could contribute to severe infection and even death. The chronic inflammatory and prothrombotic effects seen with aging can also be likely predisposing factors, aggravated by the excessive cytokine responses to a severe systemic infection (38). Major cytokines, particularly IL-6, and levels of d-dimer, which is identified as a marker of thrombin formation and active fibrinolytic activity, could also be implicated as contributing factors that progressively increase the disease process and delay recovery rate in the elderly population.

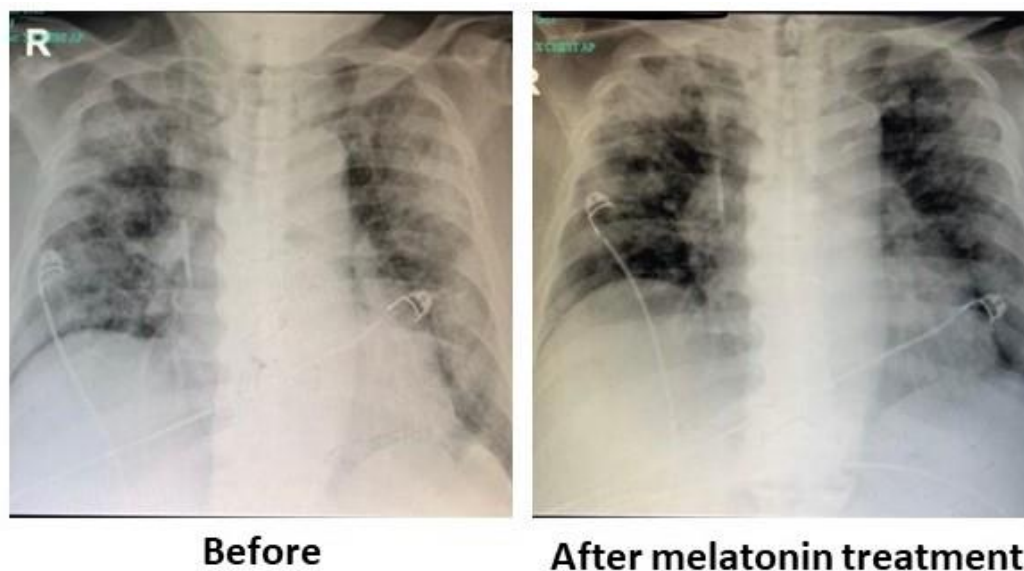


Figure 2. The representative x-ray graphs of a COVID19 patient before and after melatonin as an adjuvant treatment.

Serial chest x-rays of Patient No.1, a 64-year old male hypertensive with T2DM, CKD, chronic gout, with moderate ARDS and PFR of less than 160 mmHg. Follow-up chest x-ray showed regression of ground glass opacities after melatonin treatment but this finding persisted until discharge although patient was already symptom-free. PFR: paO_2/FIO_2 ratio (Courtesy of Department of Radiology, Manila Doctors Hospital).

An ambispective cohort study by Li *et al.*, that included 548 hospitalized patients with COVID19, showed that almost half of the cases were severe (39). Compared to non-severe conditions, prevalence of comorbidities was higher among those with severe conditions, namely: diabetes (19.3% vs. 11.1%, $p=0.009$), hypertension (38.7% vs. 22.2%, $p<0.001$) and coronary artery disease (10.4% vs. 2.2%, $p<0.001$). In this case series, among the 10 patients included, 8 had hypertension, 3 had diabetes and 2 had coronary artery disease.

A retrospective cohort study of Wu *et al.*, involving 201 patients with confirmed COVID19 pneumonia admitted to Wuhan Jinyintan Hospital, looked into risk factors in the development of ARDS and death (40). The risk factors associated with the development of ARDS and progression from ARDS to death shown in the study were older age, neutrophilia, higher lactate dehydrogenase and D-dimer. The authors also considered immune response dysfunction leading to a cytokine storm as one possible mechanism of pathogenesis of COVID19 (40).

Three of the 10 hdM patients in these case series had moderately severe ARDS, and another one had mild ARDS. None of the 10 given hdM required MV. Due to the patients' advanced age and oftentimes presence of comorbid conditions, the pro-inflammatory complications of COVID19 may have devastating effect unless adequately addressed. Due to its anti-inflammatory, anti-apoptotic and anti-oxidant properties, melatonin has a potential role as one of the treatment modalities in COVID19 (5, 41). Melatonin modulates the immune system response, reduces the pro-inflammatory cytokines levels (41) and enhances T helper immune responses (42). Melatonin, *in vitro*, has also been shown to significantly reduce the population of Th1 CD4 lymphocytes, increase the expression of anti-inflammatory cytokine IL-10 together with the population of IL-10-producing CD4 T cells (9).

HdM, up to a dose of 72 mg/day in 4 divided doses was well-tolerated in this case series. The only side-effect reported was increased sleepiness, which was deemed favorable by all patients, most of whom had anxiety- and symptom-related sleeping problems previously. Melatonin's encouraging safety profile in this case series is in keeping with literature on exogenous melatonin use. Experimental studies on mice during gestation have shown that very high doses of up to 200 mg/kg/day did not show any significant embryo/fetal toxicity (43). Andersen *et al.* detailed the possible risks of melatonin in specific patient groups and found little to no side effects even at doses given at 1 gm/day (44). To date, no studies have reported serious adverse effects of melatonin use. Even in extreme doses, short-term (days of administration) use of melatonin in both animal and humans has been consistently shown to be safe, with only mild side effects recorded such as dizziness, headache, nausea, and sleepiness (45, 46). Randomized trials have likewise recorded mild side effects comparable to placebo with long-term (years) of administration of melatonin in adults (47-49). Animal or human toxicity despite high-dose melatonin administration has not been documented (5, 43, 44, 50). There are no reports or studies elucidating neither the positive nor adverse effects of melatonin in pregnancy or lactation. In the elderly, anxiolytic and hypnotic effects of melatonin are regarded as beneficial (51).

There is a paucity of information on the use of melatonin in high-risk groups, and most studies consider the increase in sleepiness a welcome respite from the lack or interference of sleep in critically ill patients (47, 48, 50, 52, 53). A recent randomized trial reported no adverse effects or complications, and a trend towards a shorter ICU stay and total hospital stay after liver resection was noted with a single dose of 50 mg/kg body weight dissolved in 250 mL of milk via gastric tube given before surgery (54).

Melatonin has not caused serious adverse effects in studies of ALI/ARDS in mouse models (55, 56). However as with most research on melatonin for varying clinical scenarios, conclusions for its use in humans may only be extrapolated from translational research in animals, and from the limited yet indirect safety studies in humans that populate the literature (5). More studies are needed to establish concrete safety guidelines in the use of high-dose

melatonin in humans. Specifically, the effects of hdM in COVID19 pneumonia have yet to be elucidated.

In conclusion, high-dose melatonin may have a beneficial role as adjuvant therapy in patients being treated for COVID19 pneumonia, in terms of shorter time to clinical improvement, less need for intubation and MV, shorter hospital stay, and possibly lower mortality. It was well tolerated. Being a commonly available and inexpensive sleep-aid supplement worldwide, it may play a role as adjuvant therapy in the global war vs COVID19. We are preparing to undertake soon a bigger multicenter randomized clinical trial to validate the observations in this report.

ACKNOWLEDGEMENT

Members of the MAC-19 PRO Study Group: Dr. Nelson Abelardo, Dr. Petrarch Bravo, Ms. Elizabeth de Guzman-Dantes, Dr. Hian Ho Kua, Dr. Gregory Brown (University of Toronto), Dr. Harold Pupko (North York, Ontario), Dr. David Streiner (McMaster University), Dr. Romeo Merino, Dr. Bernadette Tumanan-Mendoza, Dr. Noemi Pestano, Dr. Silverose Ann Bacolcol, Dr. Camilo Te, Jr., Dr. Bernadette Mendoza, Dr. Gina Ogaco, Dr. Marjorie Obrado, Dr. Camilo Roa, Jr., Dr. Aileen Wang, Dr. Albert Albay, Jr., Dr. Elizabeth Montemayor, Dr. Arlene Afaga, Dr. Ceige Aguatis, Dr. Epifania Collantes, Dr. Marisse Nepomuceno, Dr. Sonia Salamat, Dr. Jennifer San Luis, Dr. Russel Semeniano, Dr. Clariza Santos, Dr. Lau Europa, Dr. Mina Astejada, Dr. Lourdes Padilla-Reyes, Dr. Allan Gumatay, Dr. Allan Lim, Dr. Danilo Enriquez, Dr. Daniel Morales, Dr. Grace Pancho, Dr. Jose Sarenas III, Dr. Giancarlo Arandia, Dr. Roland Santos, Dr. Trisha Lapuz, Medical Residents, Training Fellows and other Frontliners at the Manila Doctors Hospital.

Funding assistance for the MAC19 PRO Study Program was from the Department of Science and Technology-Philippine Council for Health Research and Development (DOST-PCHRD).

AUTHORSHIP

Rafael Castillo: Conception and design, analysis and interpretation of data, drafting the manuscript and revising it critically for important intellectual content, gave final approval of version to be published; Gino Rei Quizon: Acquisition of data, analysis and interpretation of data, revision of manuscript, gave final approval of version to be published; Felix Eduardo Punzalan: Analysis and interpretation of data, revision of manuscript, gave final approval of version to be published; Dante Morales: Conception and design, or analysis and interpretation of data, gave final approval of version to be published; Mario Joselito Juco: Acquisition of data, analysis and interpretation of data; Arthur Dessi Roman: Acquisition of data, analysis and interpretation of data; Donnah de Leon: Acquisition of data, analysis and interpretation of data; Rafael Bien Guingon: Acquisition of data, analysis and interpretation of data, gave final approval of version to be published. Dun Xian Tan, identification and interpretation of data; Russel J. Reiter, identification and interpretation of data, suggestions for information to be included in the paper and minor editing of the manuscript.

All authors agreed to be accountable for all aspects of the work in ensuring that questions related to the accuracy or integrity of any part of the work are appropriately investigated and resolved.

CONFLICT OF INTEREST

Rafael R. Castillo: member of speakers bureau and advisory board of Servier, Boehringer-Ingelheim, Menarini, LRI-Therapharma, AstraZeneca, Sanofi, UAP Pharma; officer and owns stocks in Trianon International and FAME Publishing with salary donated to a charitable foundation; Dante Morales: member of Board of Directors of Manila Doctors Hospital, international research grants from AstraZeneca, Bayer Pharma, PHRI Canada; chairman/member of advisory board and speakers' bureau of Astra Zeneca, LRI Therapharma, Bayer Pharma, Menarini, Pfizer, Sanofi; Mario Juco: medical director of Manila Doctors Hospital; Arthur Dessi Roman: member of speakers bureau of Sanofi, Unilab, Natrapharm, MSD, Terrumo; Felix Eduardo Punzalan: member of speakers bureau of Sanofi, Servier, Aspen, Novartis; member of advisory board of Merck, GX Pharma; Donnah de Leon, Rafael Bien Guingon, Dun Xian Tan and Russel J Reiter have no potential conflicts of interest.

REFERENCES

1. Wu C, Chen X, Cai Y, *et al.* (2020) Risk factors associated with acute respiratory distress syndrome and death in patients with coronavirus disease 2019 pneumonia in Wuhan, China. *JAMA Intern. Med.* doi: 10.1001/jamainternmed.2020.0994.
2. Mehta P, McAuley D, Brown M, *et al.* (2020) COVID-19: consider cytokine storm syndromes and immunosuppression. *Lancet* **395** (10229): 1033-1034. [https://doi.org/10.1016/S0140-6736\(20\)30628-0](https://doi.org/10.1016/S0140-6736(20)30628-0).
3. Cheung C, Poon L, Ng I, *et al.* (2005) Cytokine responses in severe acute respiratory syndrome coronavirus-infected macrophages in vitro: possible relevance to pathogenesis. *J. Virol.* **79**: 7819-7826, 10.1128/JVI.79.12.7819-7826.2005.
4. Phua J, Weng L, Ling L, *et al.* (2020) Intensive care management of coronavirus disease 2019 (COVID-19): challenges and recommendations. *Lancet* doi: [https://doi.org/10.1016/S2213-2600\(20\)30161-2](https://doi.org/10.1016/S2213-2600(20)30161-2).
5. Zhang R, Wang X, Ni L, *et al.* (2020) COVID-19: Melatonin as a potential adjuvant treatment. *Life Sci.* **250**: 117583; <https://doi.org/10.1016/j.lfs.2020.117583>.
6. Zhang Y, Li X, Grailer JJ, *et al.* (2016) Melatonin alleviates acute lung injury through inhibiting the NLRP3 inflammasome. *J. Pineal Res.* **60** (4): 405-414. doi:10.1111/jpi.12322.
7. Wu GC, Peng CK, Liao WI, *et al.* (2020) Melatonin receptor agonist protects against acute lung injury induced by ventilator through up-regulation of IL-10 production. *Respir. Res.* **21** (1): 65. doi: 10.1186/s12931-020-1325-2.
8. Srinivasan V, Kato H, Mohamed M (2012) Melatonin in bacterial and viral infections with focus on sepsis: a review. *Res. Gat.* **6** (1): 30-39 doi: 10.2174/187221412799015317.
9. Huang SH, Liao CL, Chen SJ (2019) Melatonin possesses an anti-influenza potential through its immune modulatory effect. *J. Funct. Foods* **58**: 189-198. <https://doi.org/10.1016/j.jff.2019.04.062>.
10. Calvo J, Gonzalez-Yanes C, Maldonado M (2013) The role of melatonin in the cells of the innate immunity: a review. *J. Pineal Res.* **55**: 103-120; doi:10.1111/jpi.12075- <https://onlinelibrary.wiley.com/doi/pdf/10.1111/jpi.12075>.
11. Carrillo-Vico A, Lardone P, Álvarez-Sánchez N A, *et al.* (2013) Melatonin: buffering the immune system. *Int. J. Mol. Sci.* **14** (4): 8638-8683. <https://doi.org/10.3390/ijms14048638>.
12. Nordlund J, Lerner A (1977) The effects of oral melatonin on skin color and on the release of pituitary hormones. *J. Clin. Endocrinol. Metab.* **45**: 768-774. <https://doi.org/10.1210/jcem-45-4-768>.

13. Li Y, Sha L, Zhou Y, *et al.* (2017) Melatonin for the prevention and treatment of cancer. *Oncotarget* **8**: 39896-39921. <https://doi.org/10.18632/oncotarget.16379>.
14. Barni S, Lissoni P, Cazzaniga M, *et al.* (1995). A randomized study of low-dose subcutaneous interleukin-2 plus melatonin versus supportive care alone in metastatic colorectal cancer patients progressing under 5-fluorouracil and folates. *Oncology* **52** (3): 243-245 <https://doi.org/10.1159/000227465>.
15. Lissoni P, Chilelli M, Villa S, *et al.* (2003) Five years survival in metastatic non-small cell lung cancer patients treated with chemotherapy alone or chemotherapy and melatonin: A randomized trial. *J. Pineal Res.* **35**: 12-15. Doi: 10.1034/j.1600-079X.2003.00032.x.
16. Mediavilla MD, Cos S, Sánchez-Barceló EJ (1999) Melatonin increases p53 and p21WAF1 expression in MCF-7 human breast cancer cells *in vitro*. *Life Sci.* **65** (4): 415-420. doi:10.1016/s0024-3205(99)00262-3.
17. Cos S, Mediavilla MD, Fernández R, González-Lamuño D, *et al.* (2002) Does melatonin induce apoptosis in MCF-7 human breast cancer cells *in vitro*? *J. Pineal Res.* **32** (2): 90-96. doi:10.1034/j.1600-079x.2002.1821.x.
18. Lissoni, P, Tancini G, Barni S, *et al.* (1997) Treatment of cancer chemotherapy-induced toxicity with the pineal hormone melatonin. *Support Care Cancer* **5**: 126-129. <https://doi.org/10.1007/BF01262569>.
19. Mills E, Wu P, Seely D, *et al.* (2005) Melatonin in the treatment of cancer: a systematic review of randomized controlled trials and meta-analysis. *J. Pineal Res.* **39**: 360-366. doi:10.1111/j.1600-079X.2005.00258.x.
20. Srinivasan V, Pandi-Perumal S, Spence D, *et al.* (2010) Melatonin in septic shock: some recent concepts. *J. Critic. Care* **25** (4): 656. e1-656.e6. doi:10.1016/j.jcrc.2010.03.006.
21. Carrillo-Vico A, Lardone PJ, Naji L, *et al.* (2005) Beneficial pleiotropic actions of melatonin in an experimental model of septic shock in mice: regulation of pro-/anti-inflammatory cytokine network, protection against oxidative damage and anti-apoptotic effects. *J. Pineal Res.* **39** (4): 400-408. <https://doi.org/10.1111/j.1600-079X.2005.00265.x>
22. Gitto E, Pellegrino S, Gitto P, *et al.* (2009). Oxidative stress of the newborn in the pre- and postnatal period and the clinical utility of melatonin. *J. Pineal Res.* **46**: 128-139. doi:10.1111/j.1600-079X.2008.00649.x.
23. Fehr A, Channappanavar R, Jankevicius G, *et al.* (2016) The conserved coronavirus macrodomain promotes virulence and suppresses the innate immune response during severe acute respiratory syndrome coronavirus infection. *mBio.* **7** (6): pii: e01721-16. doi: 10.1128/mBio.01721-16.
24. Huang C, Wang Y, Li X, *et al.* (2020) Clinical features of patients infected with 2019 novel coronavirus in Wuhan, China. *Lancet* **395** (10223): 497-506. [https://doi.org/10.1016/S0140-6736\(20\)30183-5](https://doi.org/10.1016/S0140-6736(20)30183-5).
25. Smits S, De Lang A, Van Den Brand J, *et al.* (2010) Exacerbated innate host response to SARS-CoV in aged non-human primates. *PLoS Pathog.* **6** (2010): e1000756-e1000756. <https://doi.org/10.1371/journal.ppat.1000756>.
26. Channappanavar R, Fehr A, Vijay R, *et al.* (2016) Dysregulated type I interferon and inflammatory monocyte-macrophage responses cause lethal pneumonia in SARS-CoV-infected mice, *Cell Host. Microbe* **19**: 181-193. <https://doi.org/10.1016/j.chom.2016.01.007>.
27. Hardeland R (2018) Melatonin and inflammation-story of a double-edged blade, *J. Pineal Res.* **65**: e12525. <https://doi.org/10.1111/jpi.12525>.
28. Shang Y, Xu SP, Wu Y, *et al.* (2009) Melatonin reduces acute lung injury in endotoxemic rat. *Chi. Med. J.* **122** (12): 1388-1393. DOI: 10.3760/cma.j.issn.0366-6999.2009.12.006.

29. Imai Y, Kuba K, Neely G, *et al.* (2008) Identification of oxidative stress and toll-like receptor 4 signaling as a key pathway of acute lung injury. *Cell* **133** (2): 235–249. <https://doi.org/10.1016/j.cell.2008.02.043>.
30. Zhao Y, Wang H, Chen W, *et al.* (2019) Melatonin attenuates white matter damage after focal brain ischemia in rats by regulating the TLR4/NF- κ B pathway. *Brain Res. Bull.* **150**: 168–178. <https://doi.org/10.1016/j.brainresbull.2019.05.019>.
31. Simpson S, Kay FU, Abbara S, *et al.* (2020) Radiological society of North America expert consensus statement on reporting chest CT findings related to COVID-19. Endorsed by the Society of Thoracic Radiology, the American College of Radiology, and RSNA. RSNA. *J. Thorac. Imaging* <https://doi.org/10.1148/ryct.2020200152>.
32. Song F, Shi N, Shan F, *et al.* (2020) Emerging 2019 novel coronavirus (2019-nCoV) pneumonia. *Radiology* **295**: <https://doi.org/10.1148/radiol.2020200274>.
33. Moore C and Bell D. (2020) Covid-19 radiology reference article. *Radiopaedia* <https://radiopaedia.org/articles/covid-19-3lang=gb>.
34. Wang Y, Dong C, Hu Y, *et al.* (2020) Temporal changes of CT findings in 90 patients with COVID-19 pneumonia: a longitudinal study. *Radiology* <https://doi.org/10.1148/radiol.2020200843>.
35. Shi H, Han X, Jiang N, *et al.* (2020) Radiological findings from 81 patients with COVID-19 pneumonia in Wuhan, China: a descriptive study. *Lancet Infect. Dis.* **20**: 425-434. [https://doi.org/10.1016/S1473-3099\(20\)30086-4](https://doi.org/10.1016/S1473-3099(20)30086-4).
36. Zhou F, Yu T, Du R, *et al.* (2020) Clinical course and risk factors for mortality of adult inpatients with COVID-19 in Wuhan, China: a retrospective cohort study. *Lancet* **395**: 1054-1062. [https://doi.org/10.1016/S0140-6736\(20\)30566-3](https://doi.org/10.1016/S0140-6736(20)30566-3).
37. Li X, Wang L, Yan S, *et al.* (2020) Clinical characteristics of 25 death cases with COVID-19: a retrospective review of medical records in a single medical center, Wuhan, China. *Int. J. Infect. Dis.* [doi:https://doi.org/10.1016/j.ijid.2020.03.053](https://doi.org/10.1016/j.ijid.2020.03.053).
38. Opal SM, Girard TD, Ely EW (2005) The immunopathogenesis of sepsis in elderly patients. *Clin. Infect. Dis.* **41** Suppl 7: S504–S512. <https://doi.org/10.1086/432007>.
39. Li X, Xu S, Yu M, *et al.* (2020) Risk factors for severity and mortality in adult COVID-19 inpatients in Wuhan. *J. Allergy Clin. Immunol.* pii: S0091-6749(20)30495-4. doi: 10.1016/j.jaci.2020.04.006.
40. Wu C, Chen X, Cai Y, *et al.* (2020) Risk factors associated with acute respiratory distress syndrome and death in patients with coronavirus disease 2019 Pneumonia in Wuhan, China. *JAMA Intern. Med.* e200994. <https://doi.org/10.1001/jamainternmed.2020.0994>.
41. Colunga Biancatelli R, Berrill M, Mohammed Y, *et al.* (2020) Melatonin for the treatment of sepsis: the scientific rationale. *J. Thorac. Dis.* **12** (Suppl 1): S54–S65. DOI: 10.21037/jtd.2019.12.85.
42. Tordjman S, Chokron S, Delorme R, *et al.* (2017) Melatonin: pharmacology, functions and therapeutic benefits. *Cur. Neuropharmacol.* **15** (3): 434–443. <https://doi.org/10.2174/1570159X14666161228122115>.
43. Jahnke G, Marr M, Myers C, *et al.* (1999) Maternal and developmental toxicity evaluation of melatonin administered orally to pregnant Sprague-Dawley rats. *Toxicol. Sci.* **50** (2): 271–279. DOI: 10.1093/toxsci/50.2.271.
44. Andersen L, Gögenur I, Rosenberg J, *et al.* (2016) The safety of melatonin in humans. *Clin. Drug Investig.* **36**: 169–175. DOI: 10.1007/s40261-015-0368-5.
45. Nordlund JJ, Lerner AB (1977) The effects of oral melatonin on skin color and on the release of pituitary hormones. *J. Clin. Endocrinol. Metab.* **45** (4): 768–774. <https://doi.org/10.1210/jcem-45-4-768>.

46. Andersen LP, Werner MU, Rosenkilde MM, *et al.* (2016) Pharmacokinetics of high-dose intravenous melatonin in humans. *J. Clin. Pharmacol.* **56** (3): 324–329. <https://doi.org/10.1002/jcph.592>.
47. Mistraletti G, Sabbatini G, Taverna M, *et al.* (2010) Pharmacokinetics of orally administered melatonin in critically ill patients. *J. Pineal Res.* **48** (2): 142–147. <https://doi.org/10.1111/j.1600-079X.2009.00737.x>.
48. Mistraletti G, Umbrello M, Sabbatini G, *et al.* (2015) Melatonin reduces the need for sedation in ICU patients: a randomized controlled trial. *Minerva Anestesiologica* **81** (12): 1298–1310.
49. Bourne RS, Mills GH, Minelli C (2008) Melatonin therapy to improve nocturnal sleep in critically ill patients: encouraging results from a small randomised controlled trial. *Critic. Care* **12** (2) R52: <https://doi.org/10.1186/cc6871>.
50. Reiter RJ, Tan DX, Maldonado MD (2005) Melatonin as an antioxidant: physiology versus pharmacology. *J. Pineal Res.* **39**: 215–216.
51. Arendt J, Skene DJ (2005) Melatonin as a chronobiotic. *Sleep Med.* **9** (1): 25–39. <https://doi.org/10.1016/j.smrv.2004.05.002>.
52. Lewandowska K, Małkiewicz MA, Siemiński M, *et al.* (2020) The role of melatonin and melatonin receptor agonist in the prevention of sleep disturbances and delirium in intensive care unit - a clinical review. *Sleep Med.* **69**: 127–134. <https://doi.org/10.1016/j.sleep.2020>.
53. Lewis SR, Pritchard MW, Schofield-Robinson OJ, *et al.* (2018). Melatonin for the promotion of sleep in adults in the intensive care unit. *Cochrane Database Syst. Rev.* **5** (5): CD012455. <https://doi.org/10.1002/14651858.CD012455.pub2>.
54. Nickkholgh A, Schneider H, Sobirey M, *et al.* (2011) The use of high-dose melatonin in liver resection is safe: first clinical experience. *Pin. Res.* **50** (4): 381–388. <https://doi.org/10.1111/j.1600-079X.2011.00854.x>.
55. Wu X, Ji H, Wang Y, *et al.* (2019) Melatonin alleviates radiation-induced lung injury via regulation of miR-30e/NLRP3 axis. *Oxid. Med. Cell Longev.* **2019**: 4087298. doi: 10.1155/2019/4087298.
56. Sun C, Lee F, Kao Y, *et al.* (2015) Systemic combined melatonin-mitochondria treatment improves acute respiratory distress syndrome in the rat. *Pin. Res.* **58** (2): 137–150. <https://doi.org/10.1111/jpi.12199>.



This work is licensed under a [Creative Commons Attribution 4.0 International License](https://creativecommons.org/licenses/by/4.0/)

Please cite this paper as:

Castillo, R.R., Quizon, G.R.A., Juco, M.J.M., Roman, A.D.E., de Leon, D.G., Punzalan, F.E.R., Guingon, R.B.L., Morales, D.D., Tan, D.-X. and Reiter, R.J. 2020. Melatonin as adjuvant treatment for coronavirus disease 2019 pneumonia patients requiring hospitalization (MAC-19 PRO): a case series. *Melatonin Research*. 3, 3 (Jun. 2020), 297-310. DOI:<https://doi.org/https://doi.org/10.32794/mr11250063>.